

# EVALUATION OF USING VENUS FREEZE™ FOR SKIN TIGHTENING AND CELLULITE TREATMENT

## Study Summary

Summarized by: Dr. Hanna Levy

### Summary

Patient demand for non-surgical, non-invasive, and no-downtime skin tightening and cellulite treatment has grown dramatically over the past decade as new treatments and technologies have been introduced.

This study was performed in order to evaluate the efficacy and safety of the Venus Freeze™, an innovative system intended for skin tightening and cellulite treatment.

### Method

Patients were treated for skin tightening and cellulite once a week for 6 to 10 weeks. In order to evaluate treatment efficacy, pre and post treatment photos were compared.

### Results

A total of 35 subjects were recruited to the study. No unexpected adverse side effects were detected or reported. All 35 patients participating in the study reported no pain during the treatment.

Photographic analysis of pre-and post treatment of the digital images revealed improvement in skin tightness, abdomen, thigh and arm circumference reduction. All patients (100%) were very satisfied from treatment results.

### Conclusions

The results of this study clearly indicate that the Venus Freeze™ system – that emits simultaneously Radiofrequency and magnetic pulses offers a non-invasive, effective, safe and virtually painless skin tightening and cellulite treatment.

## BACKGROUND

Skin aging is a multifactorial process involving the 3 layers of the skin: Epidermis, dermis and hypodermis. Skin aging process involves among others: skin roughness (epidermis), skin dyschromia (epidermis, dermis), wrinkles and elastosis - skin texture changes due to collagen modification, skin laxity and cellulite (dermis and hypodermis).

Patient demand for non-surgical, non-invasive, and no-downtime skin rejuvenation procedures has grown dramatically over the past decade as new treatments and technologies have been introduced. During this period there has been a substantial increase in the utilization of non invasive and minimally invasive skin therapy devices.

The effects of dermal heating are well recognized to include the modification of collagen structure and stimulation of neocollagenesis<sup>1</sup>. These changes in tissue collagen can help improve the appearance of fine rhytides and increase skin elasticity. These none surgical systems induce tissue tightening and contour changes through dermal collagen remodeling, by skin heating without disruption of the overlying epidermis, obviating a significant recovery period or risk of serious adverse consequences<sup>2</sup>.

Optical medical devices have been developed in the last two decades to treat signs of skin aging. While ablative lasers are used for full or partial skin ablation, intense pulsed light devices are helpful for non ablative elimination of dyschromias but provide minimal value for dermal tightening. In addition, use of optical energy devices is limited by skin color - restricting its effective use mostly to faire skinned patients.

Radiofrequency (RF) energy heats tissue by creating electric fields between two electrodes causing water molecules to rotate or move. Electrical energy can be advantageous for deep dermal heating as the movement of electrons is not impeded by tissue proteins. Radio-frequency (RF) devices had been used for many years for in a variety of surgical applications. The energy delivery systems of these established monopolar devices used a 'conductive coupling' delivery system in which energy is concentrated at the periphery of the electrode. While this was not of clinical significance

- 
1. Sadick N, Sorhaindo L. The radiofrequency frontier: a review of radiofrequency and combined radiofrequency pulsed light technology in aesthetic medicine. *Facial Plast Surg* 2005;21: 131-8.
  2. T. Alster, J. Lupton (2007). Nonablative cutaneous remodeling using radiofrequency devices. *Clin Dermatol.*;25(5):487-91.

for the incisional applications, it posed a problem for non-invasive rejuvenation as the accumulation of energy at the electrode's periphery would produce localized high concentrations of heat and burns.

Stimulation of dermal ECM (extracellular matrix) induces an immediate shrinkage of collagen fibers<sup>3,4,5</sup>. Stimulation of dermal fibroblasts by mild thermally mediated wounding induces a synthesis of new collagen fibers<sup>6</sup> (neocollagenesis), and elastic fibers (neoeLASTogenesis) after several weeks. Stimulation of skin fat cells induce an immediate increase rate of enzyme (lipase) mediated breakdown of TGs (Lipolysis) to glycerol and Free Fatty Acids (FFAs). However RF does not increase oxidation of FFAs and weight loss.

Multiple monopolar and bipolar RF devices are CE and FDA cleared for treatment of skin wrinkles and non ablative skin tightening. Although these devices offer the advantage of safely treating all skin types and color, some of them direct uncontrolled energy (monopolar/unipolar) and some of them lack the ability to penetrate deep into the tissue (simple bipolar). None of these systems offer therapy to epidermis - providing at best only a partial solution to skin aging symptoms.

Recently a novel device, Venus Freeze™ powered by (MP)<sup>2</sup> technology (Multi Polar Magnetic Pulses) was developed by Venus Technologies Mother company of Venus Concept. Through its algorithm applied via uniquely handheld Magnetic Field RF Synthesizer, (MP)<sup>2</sup> creates a highly efficient woven energy matrix.

The matrix forms a dense, energy rich field that penetrates the dermis and hypodermis.

---

<sup>3</sup> . Arnoczky S.P, Aksan A. (2000). Thermal modification of connective tissues: basic science considerations and clinical implications. *J Am Acad Orthop Surg.*; 8(5):305-13.

<sup>4</sup> Zelickson B, Ross V, Kist D, Counters J, Davenport S, Spooner G. (July 2006). Ultrastructural effects of an infrared handpiece on forehead and abdominal Skin *Dermatol Surg.*;32(7):897-901.

<sup>5</sup> Hantash BM, Ubeid AA, Chang H, Kafi R, Renton B. (2009). Bipolar fractional radiofrequency treatment induces neoeLASTogenesis and neocollagenesis. *Lasers Surg Med.*;41(1):1-9.

<sup>6</sup> . Brian D. Zelickson, MD; David Kist, BA; Eric Bernstein, MD et al. (2004) Histological and Ultrastructural Evaluation of the Effects of a Radiofrequency- Based Nonablative Dermal Remodeling Device. A Pilot Study/*Arch Dermatol.*;140:204-209.

Each electrode simultaneously emits RF and magnetic pulses in varying phases that homogeneously cause supra normal temperatures over the treated area.

Heat distribution allows overall lower energy, that minimizes the risk of side effects and completely eliminates the need for skin cooling. The supra normal temperatures in the dermis, induced by the RF, break a small number of consecutive hydrogen bonds and cause an immediate unfolding and shrinkage of collagen fibers making the fibers shorter & thicker<sup>7,8</sup>. The mild thermally mediated RF wounding stimulates the dermal fibroblasts to increase synthesis of new collagen fibers<sup>9,10</sup> as well as elastic fibers after several weeks.

Radiofrequency decreases fat cell volume by increasing the breakdown of triglyceride (Lipolysis) in the subcutaneous fat layer with lipotransfer<sup>11</sup> (but no weight loss). Pulsed Magnetic Fields (PMF) significantly increase production of collagen fibers by dermal fibroblasts<sup>12,13</sup>, not via thermal mechanisms<sup>14</sup>, and stimulate angiogenesis<sup>15</sup>.

---

<sup>7</sup> Wright NT, Humphrey JD. Denaturation of collagen via heating: an irreversible rate process. *Annu Rev Biomed Eng.* 2002;4:109-28.

<sup>8</sup> Zelickson BD, Kist D, Bernstein E, et al., Histological and ultrastructural evaluation of the effects of a radiofrequency-based Nonablative dermal remodeling device: a pilot study. *Arch Dermatol.* 2004;140:204-9

<sup>9</sup> Hantash BM, Ubeid AA, Chang H, Kafi R, Renton B Bipolar fractional radiofrequency treatment induces neoeelastogenesis and neocollagenesis. *Lasers Surg Med.* 2009;41:1-9.

<sup>10</sup> Brian D. Zelickson, MD; David Kist, BA; Eric Bernstein, M et al. Histological and Ultrastructural Evaluation of the Effects of a Radiofrequency-Base Nonablative Dermal Remodeling Device. A Pilot Study. *Arch Dermatol.* 2004;140:204-209.

<sup>11</sup> Emilia del Pino M, Rosado RH, Azuela A, et al. Effect of controlled volumetric tissue heating with radiofrequency on cellulite and the subcutaneous tissue of the buttocks and thighs. *J Drugs Dermatol.* 2006;5:714-22.

<sup>12</sup> Akira Soda et al. Effect of exposure to an extremely low frequency-electromagnetic field on the cellular collagen with respect to signaling Pathways in osteopath-like cells. *J Med Invest.* 2008;55:267-78.

<sup>13</sup> Shain A, Saeed RZ and Bahram B. The effects of extremely low pulsed electromagnetic field on collagen synthesis of rare skin: a Biochemical and Histological approach. *J. Iranian Biomedical Journal.* 2006;10:33-38

<sup>14</sup> Murray JC, Farndale RW. Modulation of collagen production in cultured fibroblasts by a low-frequency, pulsed magnetic field. *Biochim Biophys Acta.* 1985 Jan 28;838:98-105.

<sup>15</sup> Tepper OM, Callaghan MJ, Chang EI, et al. Electromagnetic fields increase in vitro and in vivo angiogenesis through endothelial release of FGF-2. *FASEB J.* 2004;18:1231-3.

The above interrelated biological effects induced by RF and PMF (shrinkage of collagen fibers, synthesis of new collagen and elastic fibers, lipolysis and angiogenesis) are important components to produce short and long visual results. This results are obtained through dermal collagen remodeling, and effect on subcutaneous fat layer without disruption of the overlying epidermis, obviating a significant recovery period or risk of serious adverse consequences.

In order to evaluate the effect of using Venus Freeze™ device, Venus Technologies has performed in vivo study. The study was performed on a section of static pork meat. Study results indicated that the heating effects of Venus Freeze (MP)<sup>2</sup> has the ability to raise the body temperature fairly quick and maintain the heat inside various depth of skin layers for a while.

The objective of the present study was therefore to investigate the safety and effectiveness of the Venus Freeze™ device for skin tightening and cellulite treatment.

## **METHODS**

### **Subjects**

A total of 35 participants, (10 men and 25 women ages 27-65 year) were enrolled in the study after meeting all inclusion/exclusion criteria. During the study the participants were instructed not to change their nutrition and exercise habits.

### **Procedure**

Treatment Sessions were conducted once a week for a period of 6 to 10 weeks. Each session lasted 20 to 60 minutes.

The treated area was chosen by the participants, according to their needs and included: abdomen, buttock, thighs, and arms.

The treatment area was cleaned thoroughly with soap and water. The skin surface was dried prior to the treatment. Immediately after the treatment the treated area was visually assessed for skin responses, including edema, erythema, hypopigmentation, hyperpigmentation, and textural changes.

Clinical photographs and measurements were taken before and after treatments by the same operator in the same conditions to assess circumference and textural changes induced by the treatment. The pictures were taken while the participant stood in front

of a chart with vertical and horizontal lines with the camera placed at the same height distance and with the same lightening.

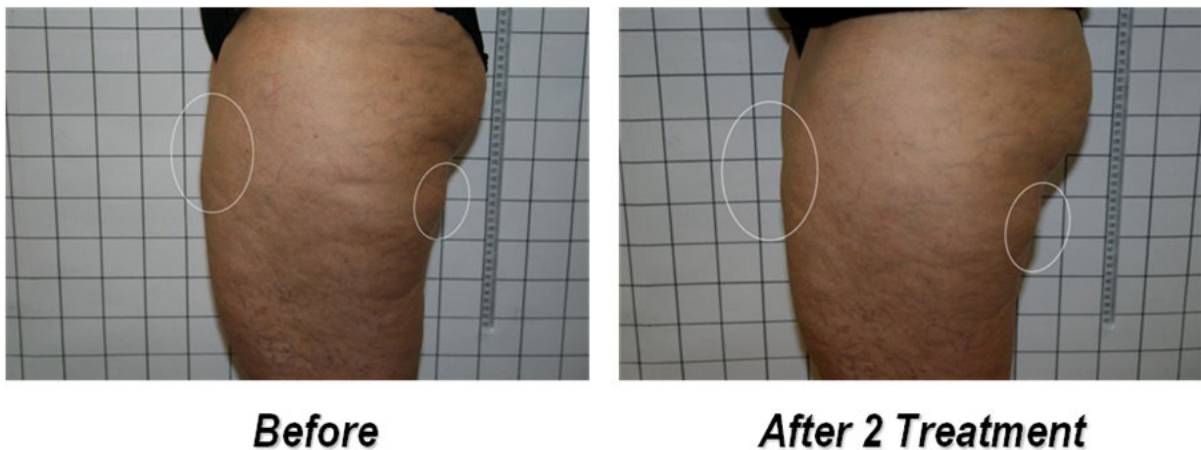
The measurements of circumference were taken from reference points in a very accurate way with measurement tape at 2 or 3 points. All data was condensed and processed using Microsoft Excel.

The safety of the procedure was also evaluated by monitoring the occurrence of potential procedure-related side effects. The treated areas were visually assessed for skin responses, including edema, erythema, hypopigmentation, hyperpigmentation, and textural changes following each treatment.

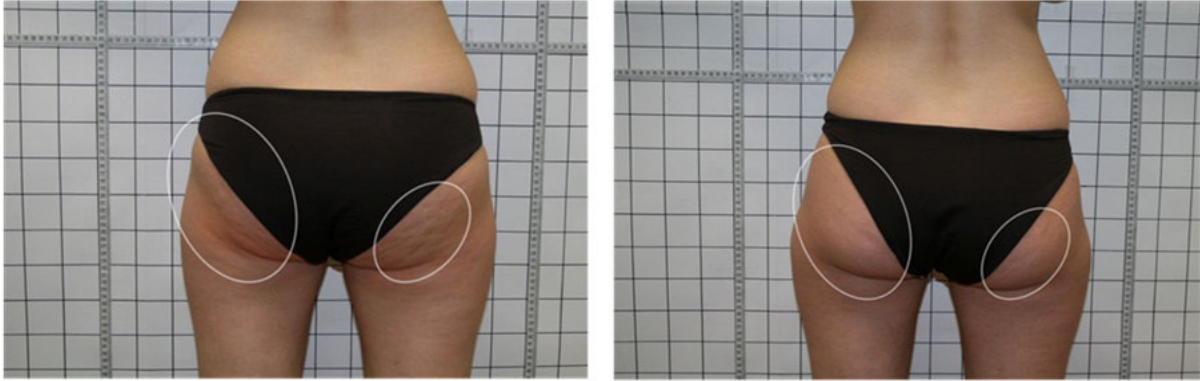
## **RESULTS AND CONCLUSIONS**

All 35 patients completed the course of the treatment protocol. No unexpected adverse side effects were detected or reported. No patients experienced burns, skin breakdown, or scarring. None of the patients has reported pain during the study.

All patients (100%) were very satisfied from treatment results. The following sets of before and after photographs (Figure 1, 2, 3 and 4) illustrate the significant beneficial effect achieved by this Venus Freeze™ System.



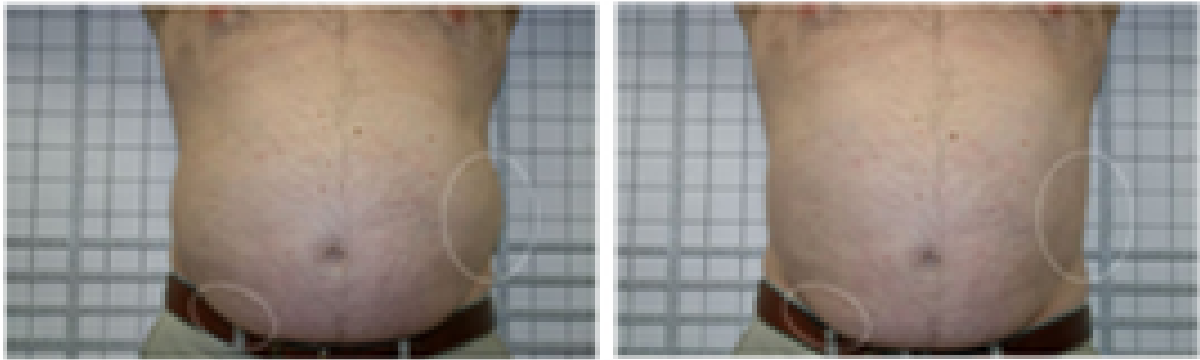
**Figure 1:** Texture and elasticity improvement following 2 treatments



***Before***

***After 1 Treatment***


**Figure 2:** Cellulite improvement following 1 treatment.



***Before***

***After 6 Treatments***

**Figure 3:** Abdomen circumference improvement following 6 treatments



***Before***

***After 6 Treatments***

**Figure 4:** Thigh circumference improvement following 6 treatments.

All participants showed improvement of all treated areas. Skin's texture and elasticity

have shown an improvement following second treatment (Fig 1). Participants which were treated for cellulite showed significant improvement following the first treatment (Fig 2). Average of 3.9 cm reduction of abdomen circumference was achieved following 6 treatments (Fig 3); this result was shown at twenty three (out of 35) participants. Most of study participants show average of 2.1 cm abdomen circumference immediately after the first treatment. In addition, average reduction of 3.2 cm of thigh circumference was achieved following 6 treatments (Fig 4). Buttocks lifting were seen for all participants following the first treatment and along the sessions. Arms' circumference was reduced in average of 2cm and the skins tonus and elasticity has been improved immediately. No side effect were observed or reported.

## **DISCUSSION AND CONCLUSIONS**

Thirty five patients were treated for skin tightening and cellulite reduction once a week for 6 to 10 weeks. In order to evaluate treatment efficacy, pre and post treatment photos were compared.

The data reported in this study demonstrate that this RF and magnetic pulses device offers a safe and effective noninvasive technique to improve the appearance of age-related rhytides and lax skin.

The clinical results of nonablative RF skin tightening effects were first reported in the periorbital area<sup>16</sup>. In this multicenter study, Fitzpatrick and his colleagues demonstrated clinical improvement in periorbital rhytides in 80% of subjects. In contrast, in 24 patients who underwent a single RF treatment to improve the upper third of the face, only 36% of the patients' self-assessment reported improvement<sup>17</sup>.

In a similar device, it has been reported that the use of a RF device was associated with significant pain, and in a small but significant number of cases subcutaneous fat atrophy

---

<sup>16</sup> Fitzpatrick R, Geronemus R, Goldberg D, et al; *Multicenter study of noninvasive, radiofrequency for periorbital tissue tightening*. *Lasers Surg Med* 2003;33:232–42.

<sup>17</sup> Bassichis BA, Dayan S, Thomas JR; *Use of Nonablative radiofrequency device to rejuvenate the upper one-third of the face*. *Otolaryngol Head Neck Surg* 2004;130: 397–406.



developed<sup>18</sup>. No subcutaneous fat atrophy was noted in this study. All patients participating in the study have reported no pain during treatment, though procedure was performed without using any anesthetic agents. Furthermore, no patients considered the procedure intolerable at any session.

The results of this study clearly indicate that this innovative Venus Freeze™ device offers a non-invasive, effective, safe and virtually painless skin tightening and cellulite treatment.

In conclusion, the data reported in this study support the safety and effectiveness of the Venus Freeze™ System for skin tightening and cellulite reduction treatment.

---

<sup>18</sup> Biesnman BS. Radiofrequency Devices: *Monopolar vs bipolar vs radiofrequency plus laser; indications; treatment approaches; novel applications; results*. In: Arndt KA, Dover JS, Anderson RR, editors. *Controversies and Conversations in Laser and Cosmetic Surgery. Symposium Proceedings*; 2005, Denver, CO.